



Depressed Broiler with ruffled feathers



Depressed Layer with flaccid comb



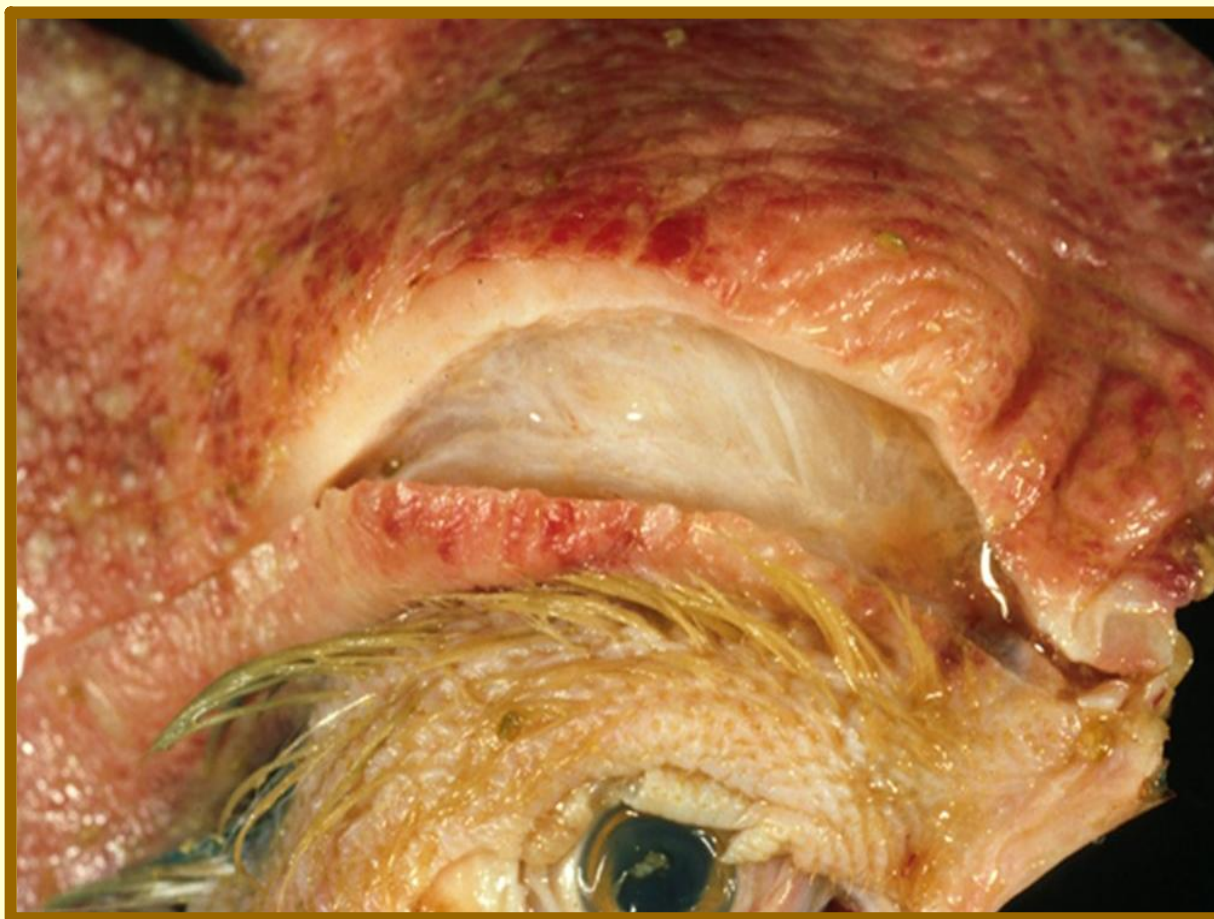Ataxia and Torticollis



Torticollis and Green Diarrhea



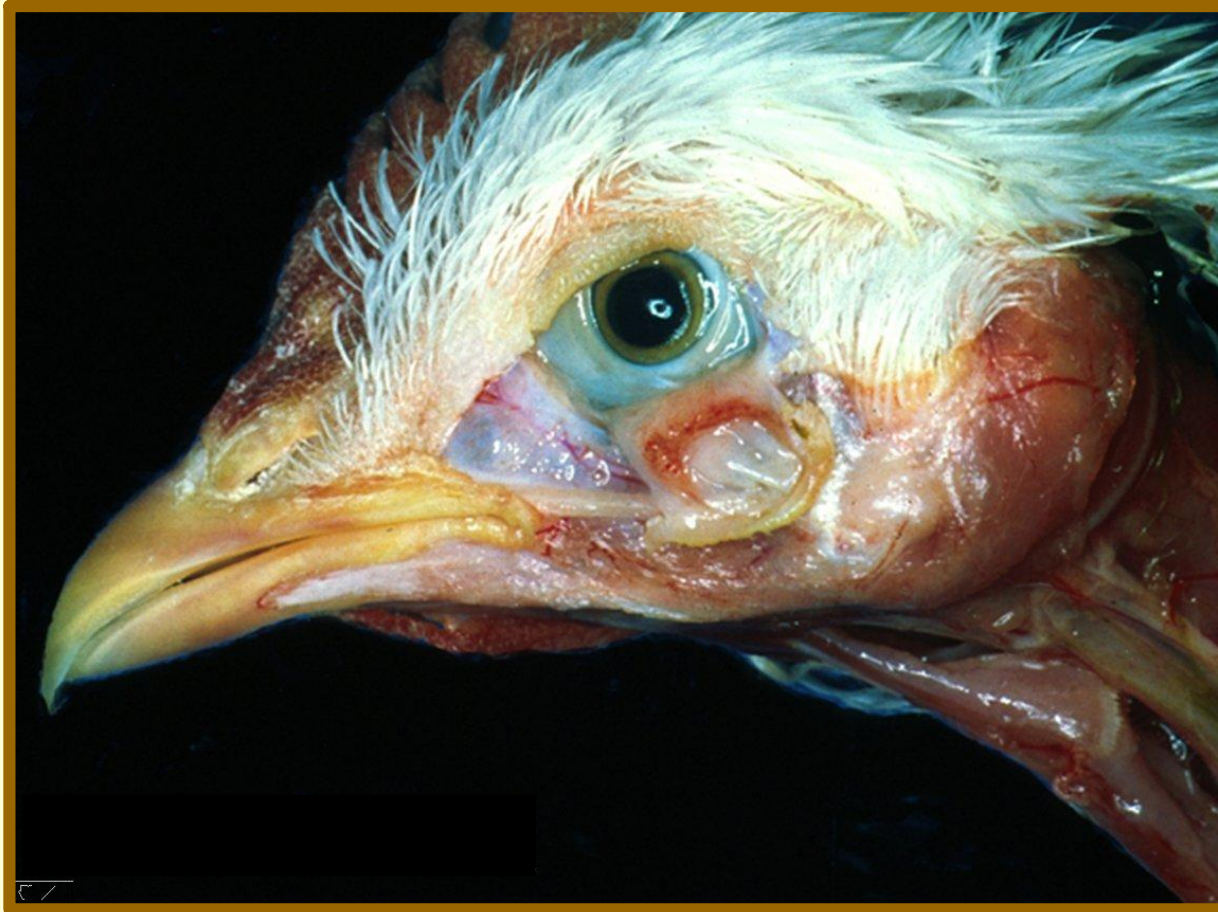Cyanotic and Edematous Combs and Wattles



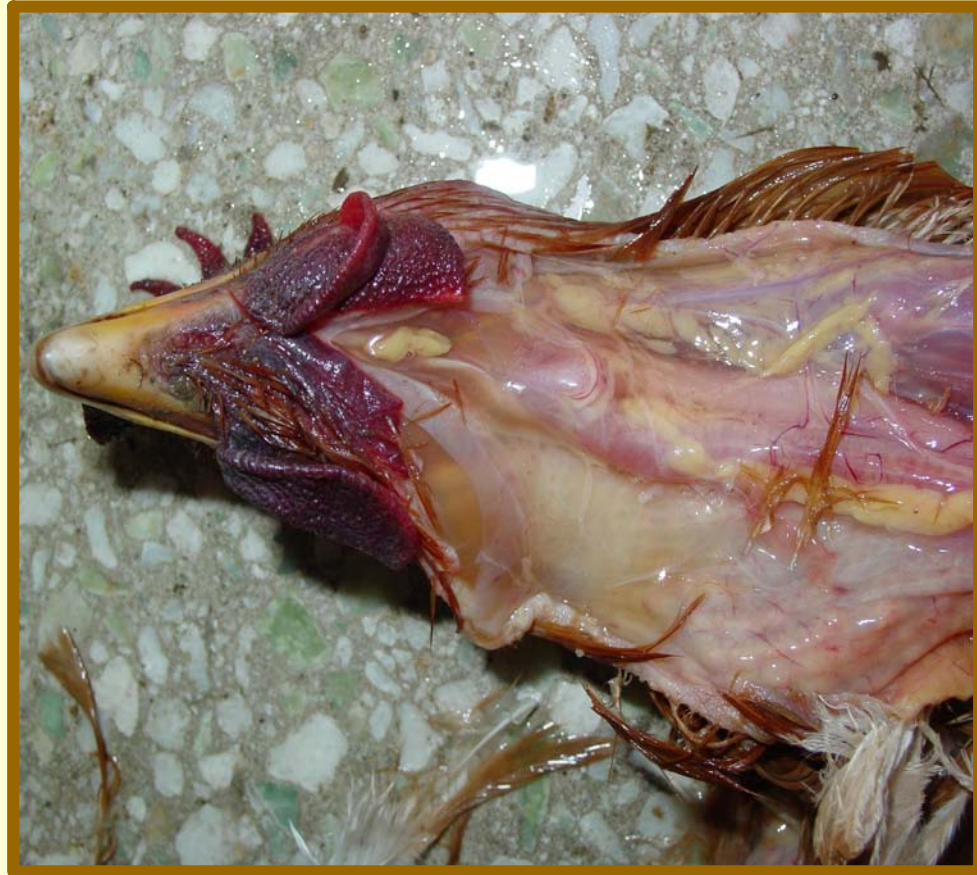Edematous Comb



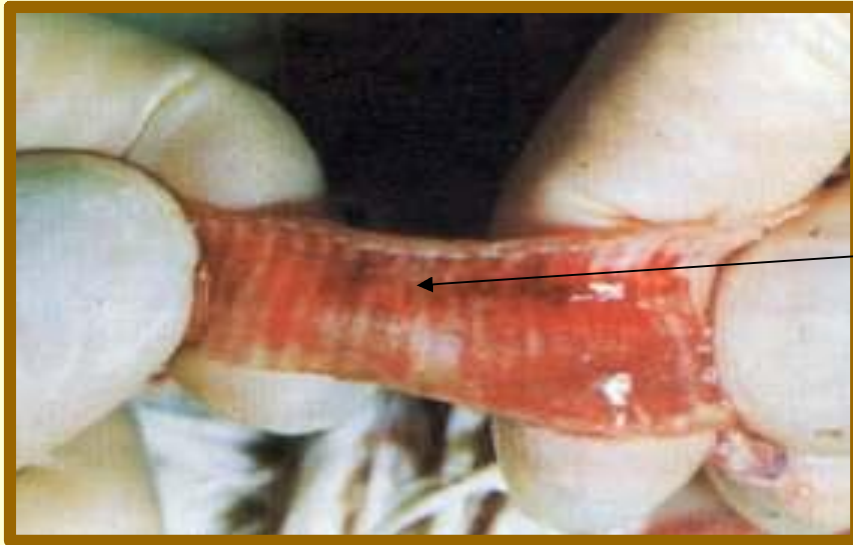
Periorbital Edema



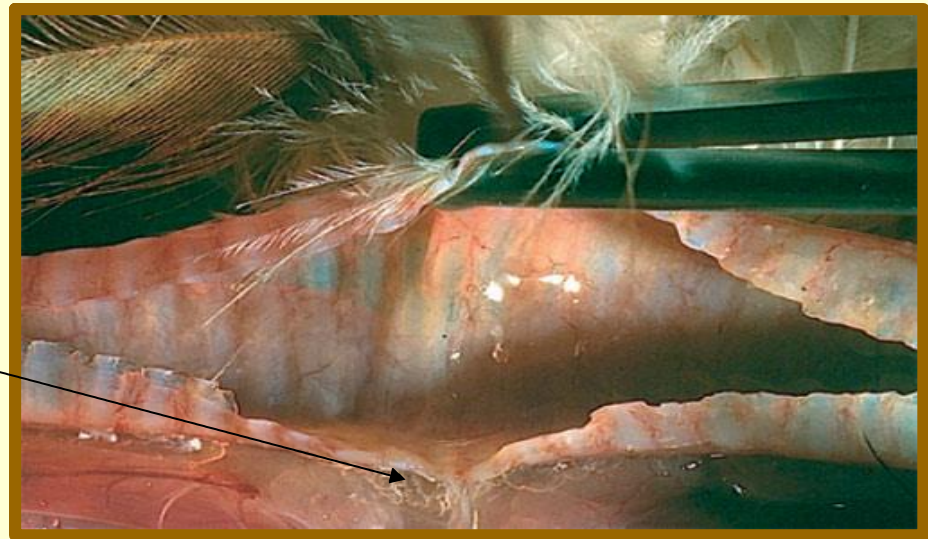
Periorbital Subcutaneous Edema



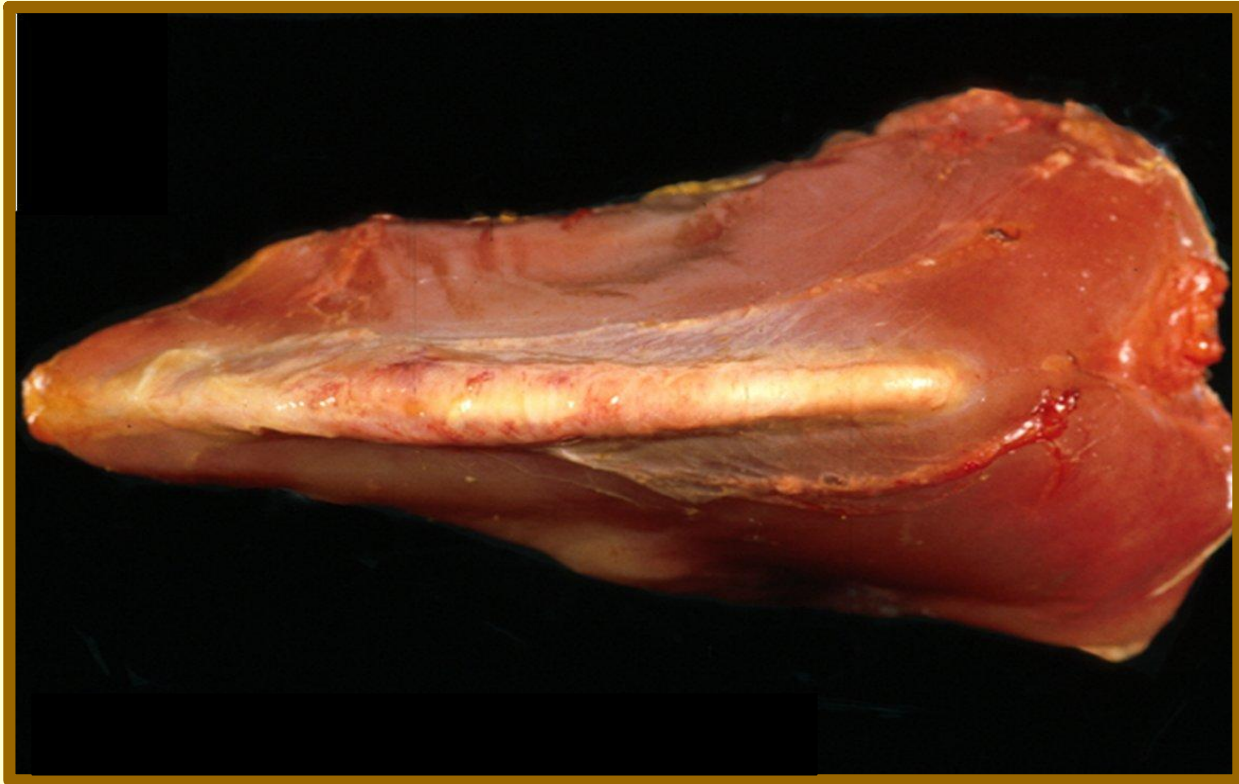Cervical Subcutaneous Edema



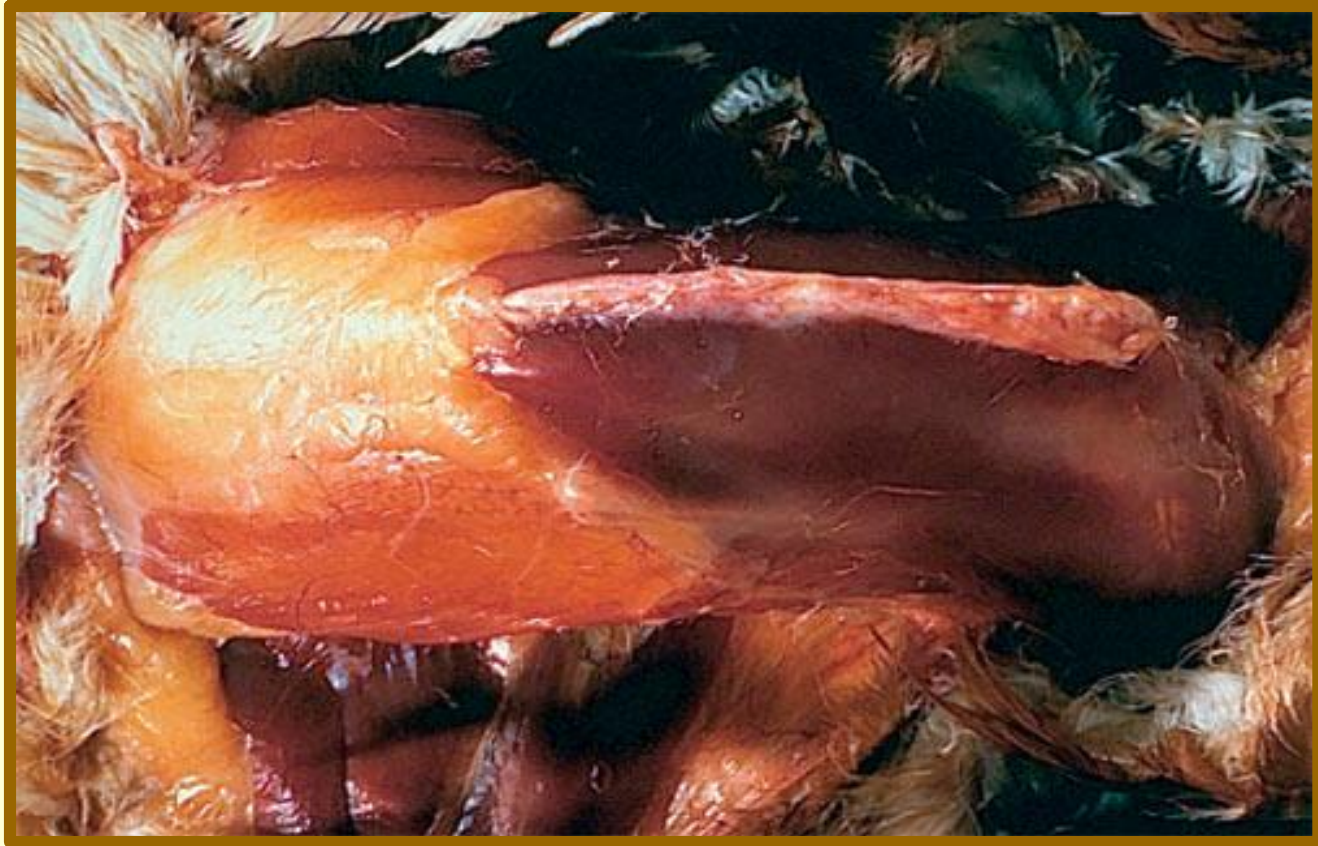Hemorrhagic Tracheitis



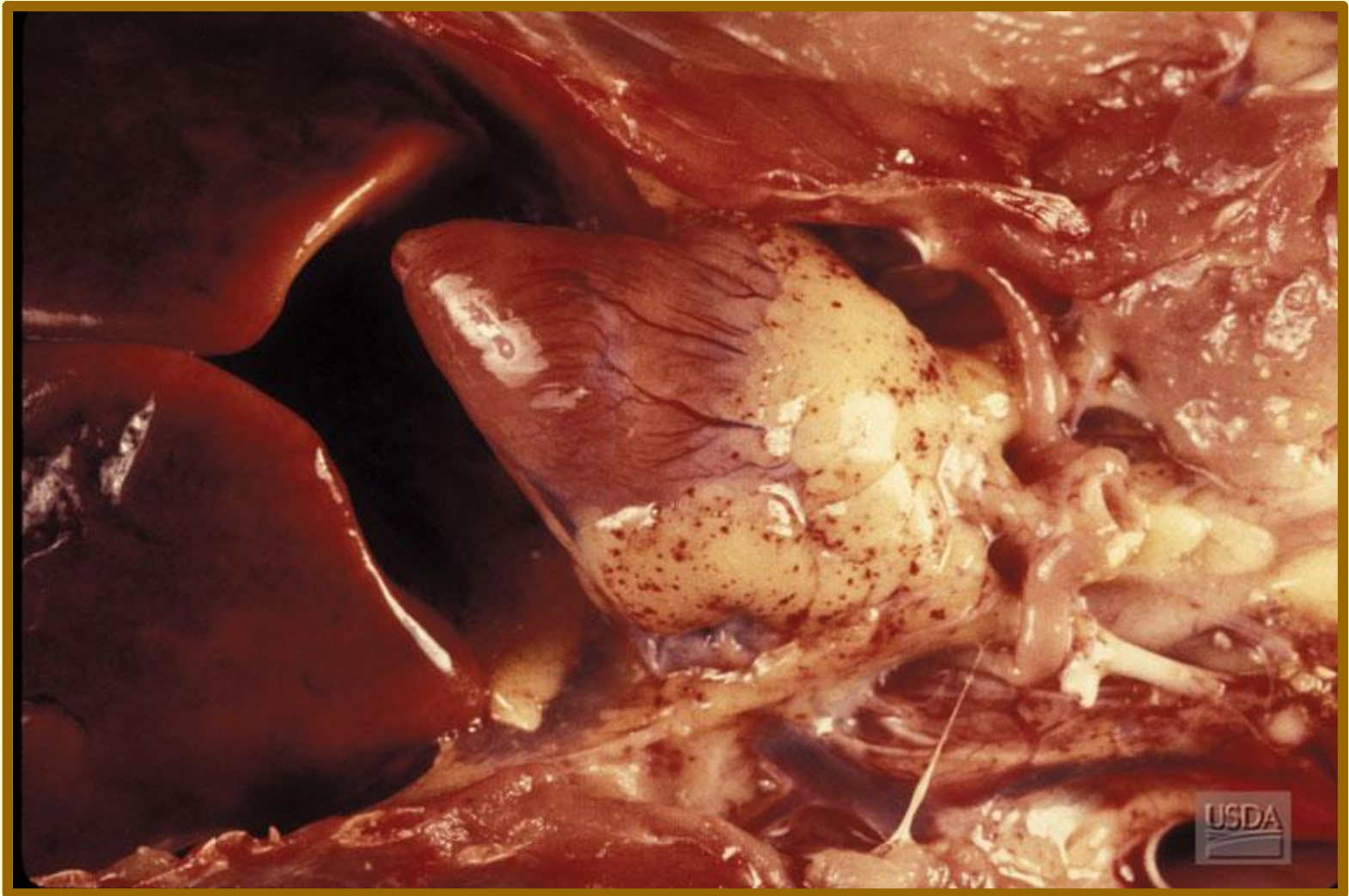
Mucous Exudate



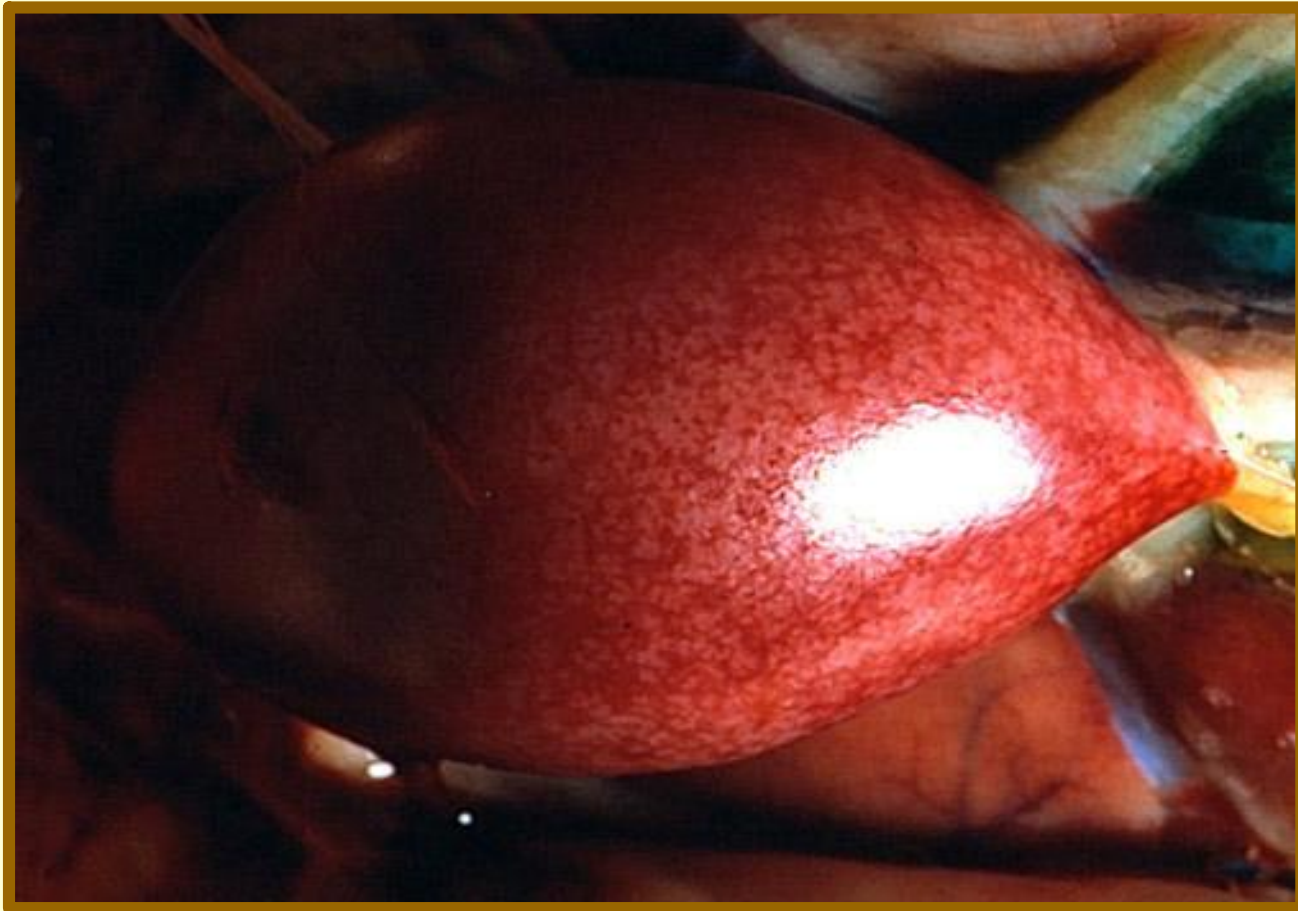
Keel Edema



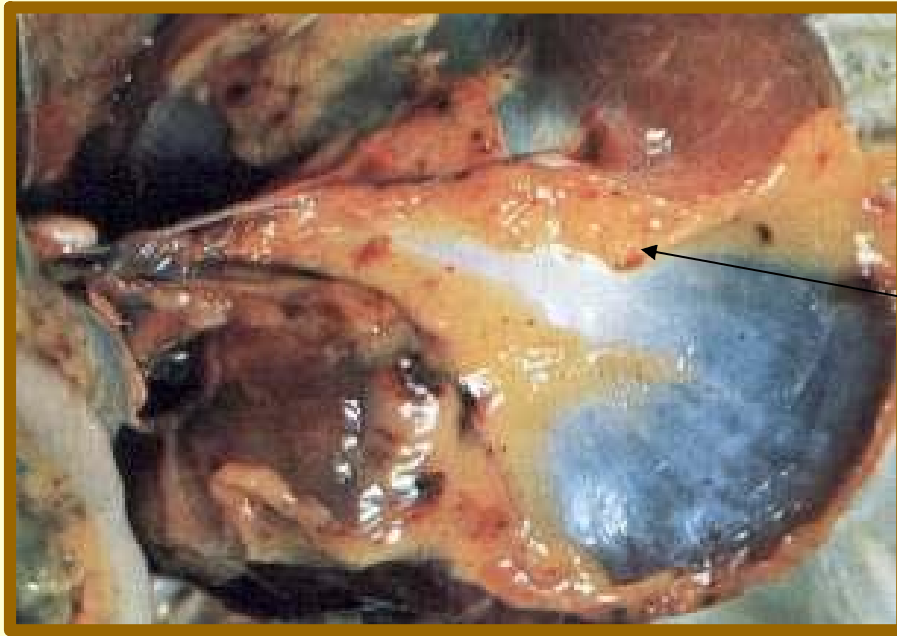
Keel Dehydration



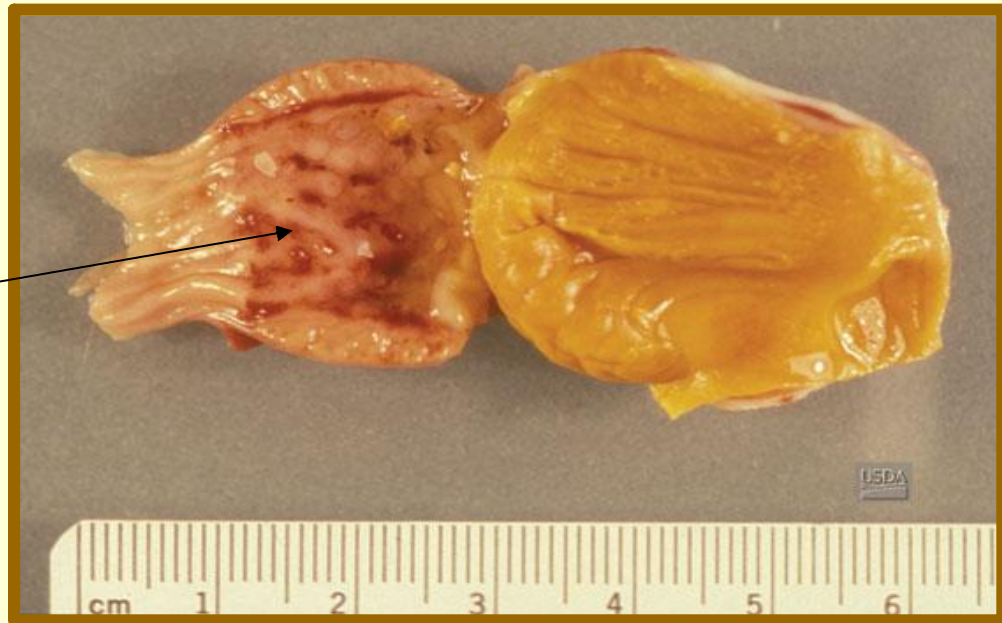Pericardial Petechial Hemorrhages



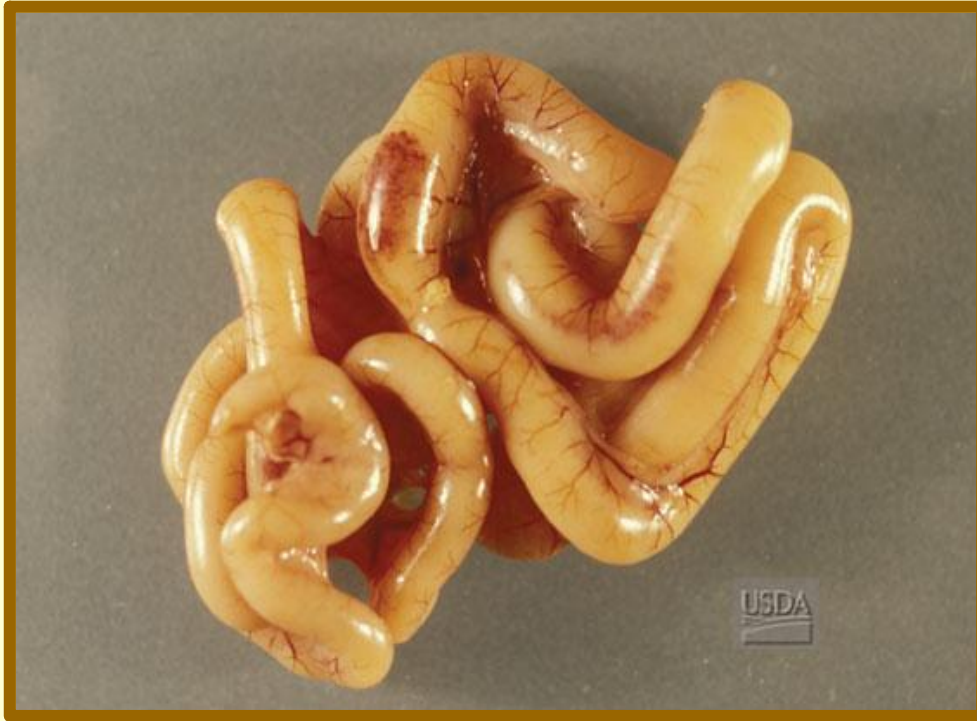Necrotic Foci in the Spleen



Hemorrhages on the gizzard

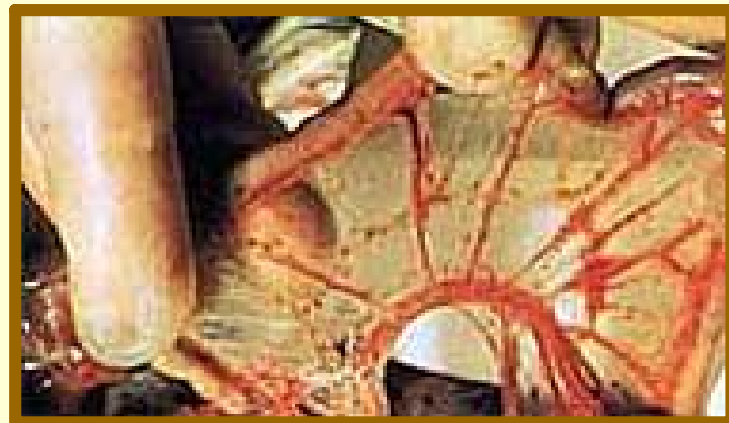

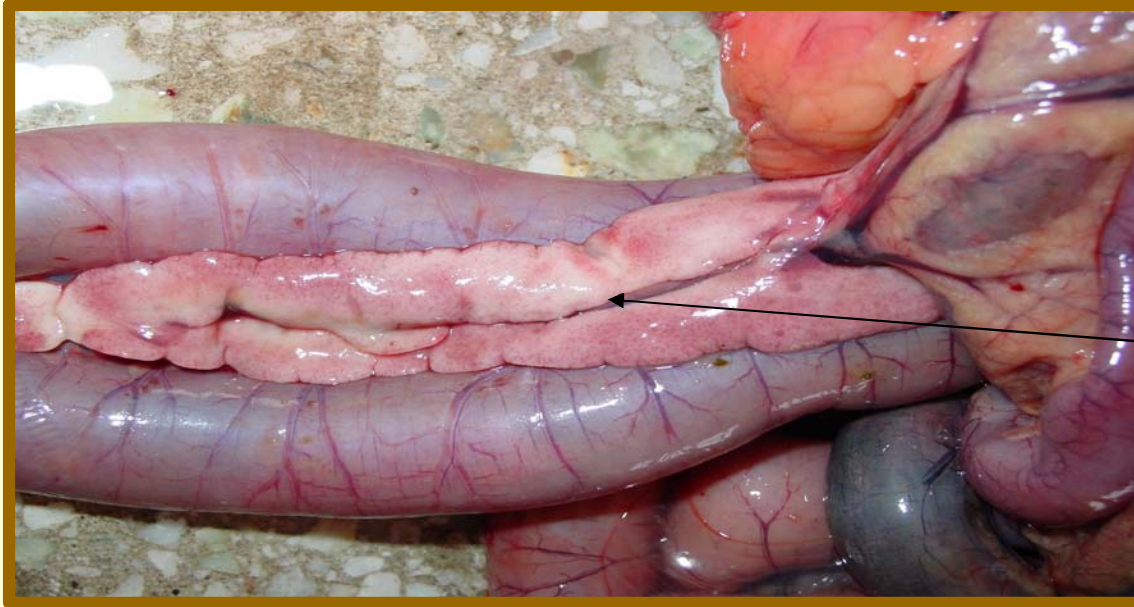Hemorrhages in the proventriculus



Serosal Hemorrhages
Over Peyer's Patches

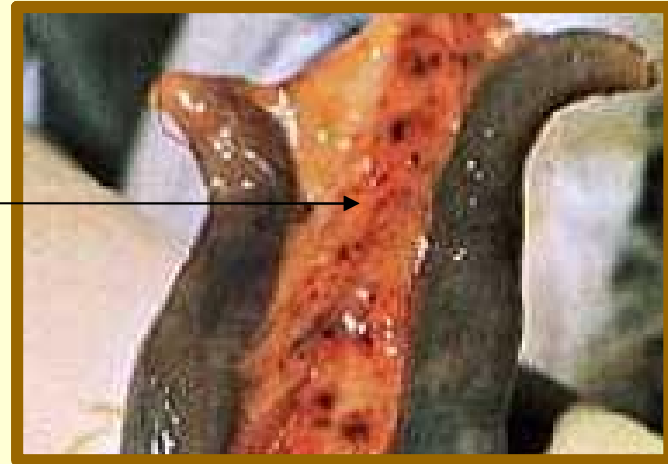Petechia in the Mesentery

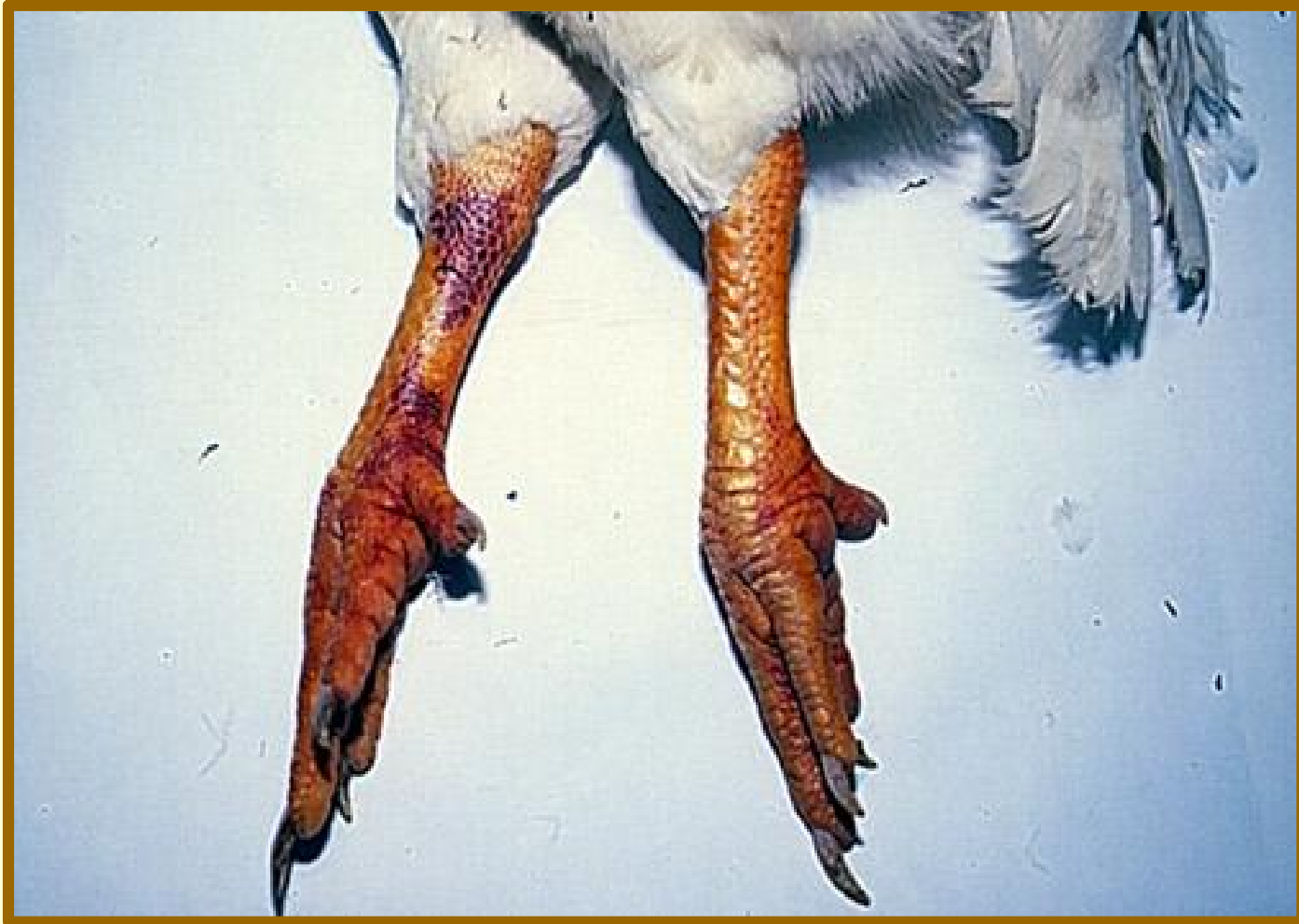



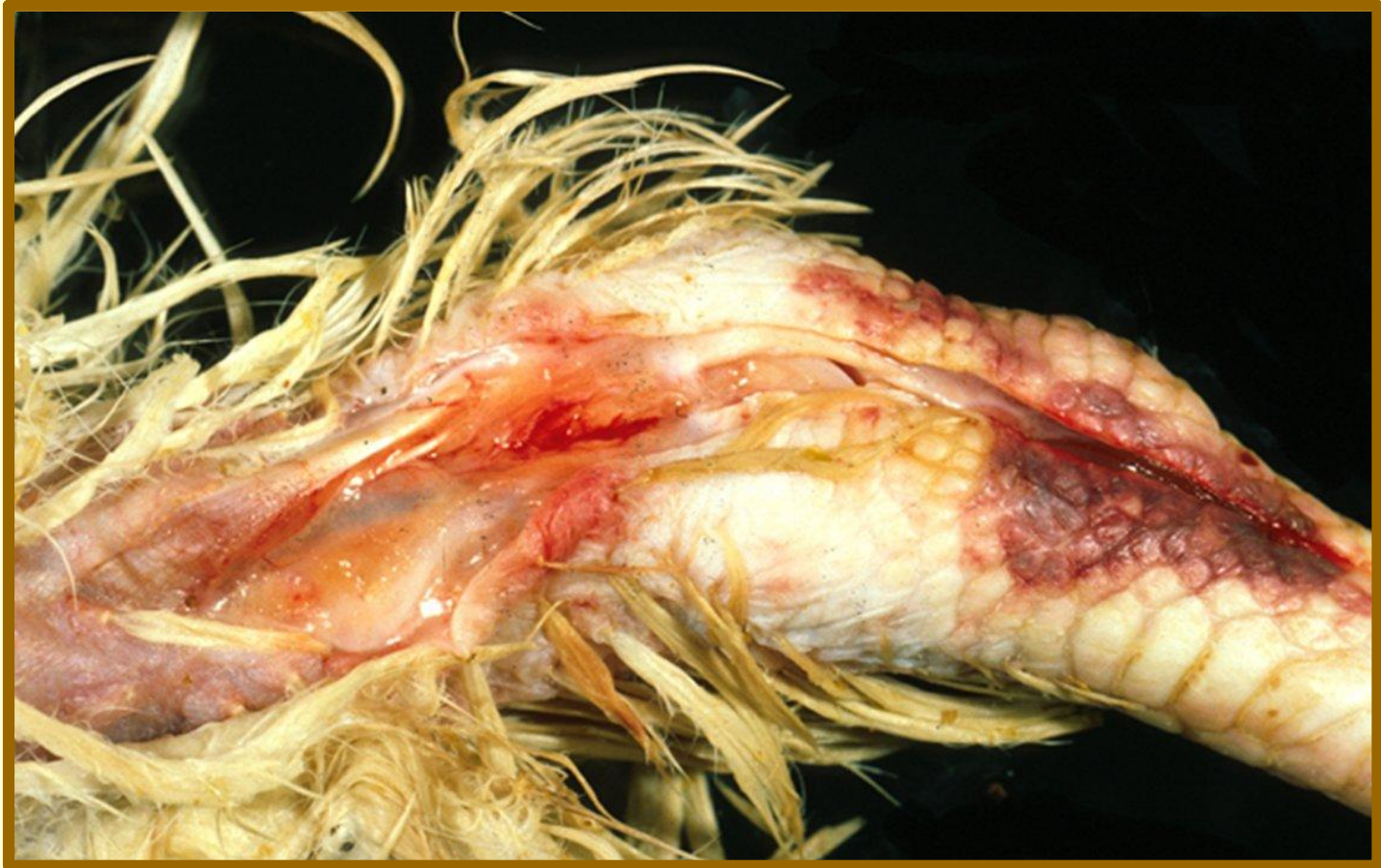Pancreatic
Edema

Petechia between
the Ceca





Hemorrhage and Edema in Hocks



Subcutaneous Hemorrhage and Edema in the Hock