

# Miscellaneous Parasitic Diseases

---

Free-ranging wild birds are afflicted with numerous other parasites that occasionally cause illness and death. Some of these parasites, such as two of the trematodes or flukes highlighted below, can cause major die-offs. This section about parasitic diseases concludes with descriptions of some additional parasites that field biologists may encounter in wild birds. This listing is by no means complete and it is intended only to increase awareness of the diversity of types of parasites that might be encountered during examinations of wild birds. One should not assume that the parasites found during the examination of bird carcasses caused their death. Because parasites of birds vary greatly in size from a protozoa of a few microns in length to tapeworms of several inches in length and because they can be found in virtually all tissues, body cavities and other locations within the bird, the observation of the parasites will depend on their visibility and the thoroughness of the examination. Therefore, it is generally beneficial to submit bird carcasses to qualified disease diagnostic laboratories to obtain evaluations of the significance of endoparasites or of ectoparasites. The methods that are used to preserve the carcass, tissues, or other specimens can enhance or compromise the ability of specialists to identify the parasite to species, and even to genera, in some instances. Therefore, whenever possible, it is best to contact the diagnostic laboratory that will receive the specimens and obtain instructions for collecting, preserving, and shipping field samples (See Chapters 2 and 3).

## Endoparasites

### Trematodes

Most trematodes or flukes have complex life cycles that require two intermediate hosts (Fig. 35.1) in which the parasites develop before they become infective for the definitive, final bird host. In general, a mollusc is the first intermediate host, and is often a species that lives in the aquatic environment. Therefore, the aquatic environment brings potential hosts (waterbirds) and these parasites into close proximity and results in infections of waterfowl and other waterbirds that sometimes have fatal consequences.

*Sphaeridiotrema globulus* is a small trematode less than 1 millimeter in length that has been reported to cause die-offs in waterfowl, especially in diving ducks and swans, and, occasionally, in coot. Birds become infected by eating snails (the second intermediate host) that are infected with the metacercarial stage of the parasite (Fig. 35.1). This trematode feeds on blood, leading to severe blood loss and anemia. Birds often die acutely from shock due to an abnor-

mally decreased volume of circulating plasma in the body or hypovolemic shock. Die-offs usually occur in the late summer or early fall and have been reported in the United States most commonly in the Northeast and North Central States, with a few reports from Western States. Die-offs will often recur yearly at the same locations. For example, mortality from *S. globulus* is suspected as a recurring event on the St. Lawrence River in southern Quebec. Infections by *S. globulus* have also been found elsewhere in Canada. The trematode is also present in the Old World and in Australia. Field signs include lethargy and bloodstained vents, although these signs are also found with duck plague (See Chapter 16). Gross lesions can appear as an inflammation or enteritis that is characterized by obvious hemorrhages in the lower small intestine or as inflammation of the intestinal wall with areas of ulcer-like erosions and the presence of a mixture of blood and fibrin (Fig. 35.2).

Experimental infections of mute swans with *S. globulus* indicated that as few as 100 metacercariae could be lethal. Juvenile mallard ducks that had no previous exposure to *S. globulus* died when infected with 550 metacercariae. Some immunity has been shown to exist in experimental infections of mallards. Adult mallards that were given 100 metacercariae and that later were challenged with 2,500 metacercariae survived, but those that received only 2,500 metacercariae died. Depending on how heavily snail populations are infected, some birds can receive a lethal dose during less than 24 hours of feeding. Susceptible waterfowl generally die 3–8 days postinfection after ingesting a lethal dose of *S. globulus*. Younger birds are generally more susceptible than older birds.

No parasite control measures have been developed. Any attempts at control would need to take into account the fact that the intermediate hosts are different within different geographic areas of the United States. There have been no reports of this parasite infecting humans.

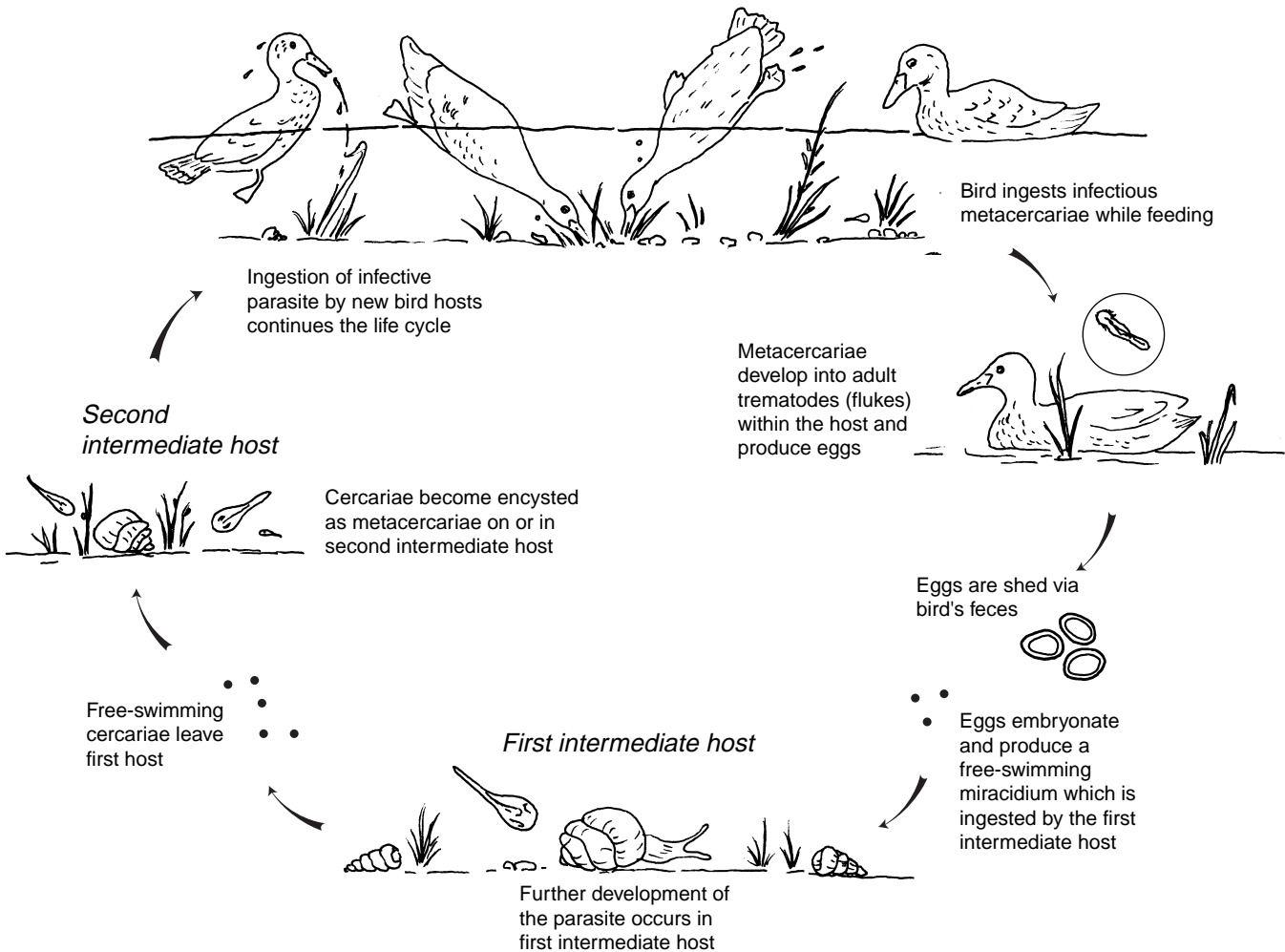
*Cyathocotyle bushiensis* is another trematode that infects waterfowl and coot in the United States and Canada. This trematode can be found in the lower intestine, most commonly in the cecae or blind pouches extending out from the beginning of the large intestine (Fig. 35.3). The worms are slightly larger than *S. globulus*, measuring 1.7–1.8 millimeters in length. The life cycle for this parasite is similar to that of *S. globulus*. Birds become infected by consuming snails harboring the metacercariae. Disease caused by this trematode has been reported in black duck, blue-winged teal, green-winged teal, and coot. This trematode was first described in England and it is most likely limited by the geographic dis-

tribution of the snail, *Bithynia tentaculata*, which serves as the first intermediate host. This snail is found within the Great Lakes Basin in the United States.

There are no field signs associated with infection by *C. bushiensis* that have any diagnostic value. Common gross lesions in birds include hemorrhagic areas with plaque formation and some cheese-like or caseous core formation in the lumen of the cecae. Hemorrhage and plaque formation within the cecae are often present during early stages of infections (5–7 days after infection), whereas semisolid cellular debris that plugs the cecae are found in later infections (day 9 and later). Tissue damage within the birds is directly related to the attachment of the fluke to the mucosa and the effect of secretions by the fluke on cellular process within the intestine. Studies have indicated that there is a negative relationship between the number of flukes present and weight gain by the bird and a positive relationship between the num-

ber of flukes present and the number of white blood cells and body temperature. These findings reflect the nutritional impacts (reduced weight gain or weight loss) and body response to infection (increased white blood cells and body temperature). It is not known if weight loss in infected birds is due to cecal and lower intestine dysfunction or if the birds do not feed as much as noninfected birds. It has been suggested that morbidity and mortality are directly related to vascular leakage in the cecae from tissue damage that leads to dehydration of the bird. Experiments have shown that a fluke burden as low as 32 resulted in deaths of Pekin ducklings on day 8 postinfection, which indicates that ducks may succumb rather quickly to infection.

Control of this parasite, as for all trematode infections, would require preventing birds from feeding on infected snails or other invertebrate intermediate hosts. No reports of human infection have been reported for this trematode.



**Fig. 35.1** General trematode (flake) life cycle.

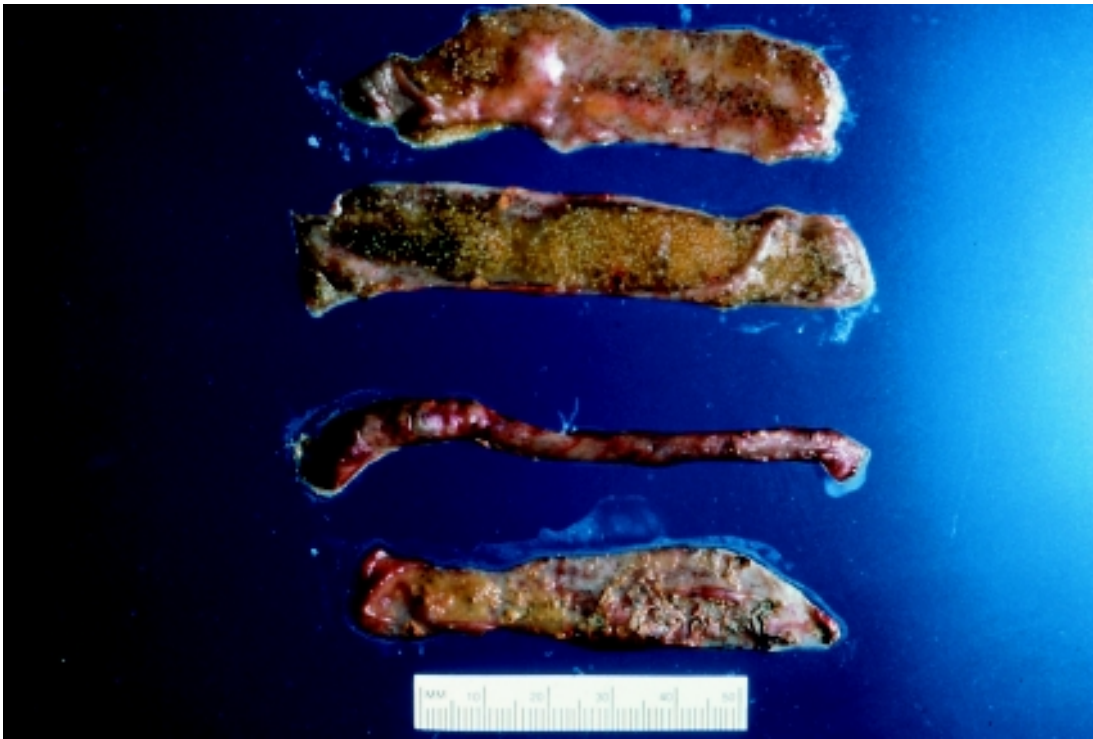


Photo by James Runnigen

**Fig. 35.2** Small intestine of lesser scaup that died from infection with *Sphaeridiotrema globulus*. Note the white flecks, which are *S. globulus*, and obvious hemorrhage.

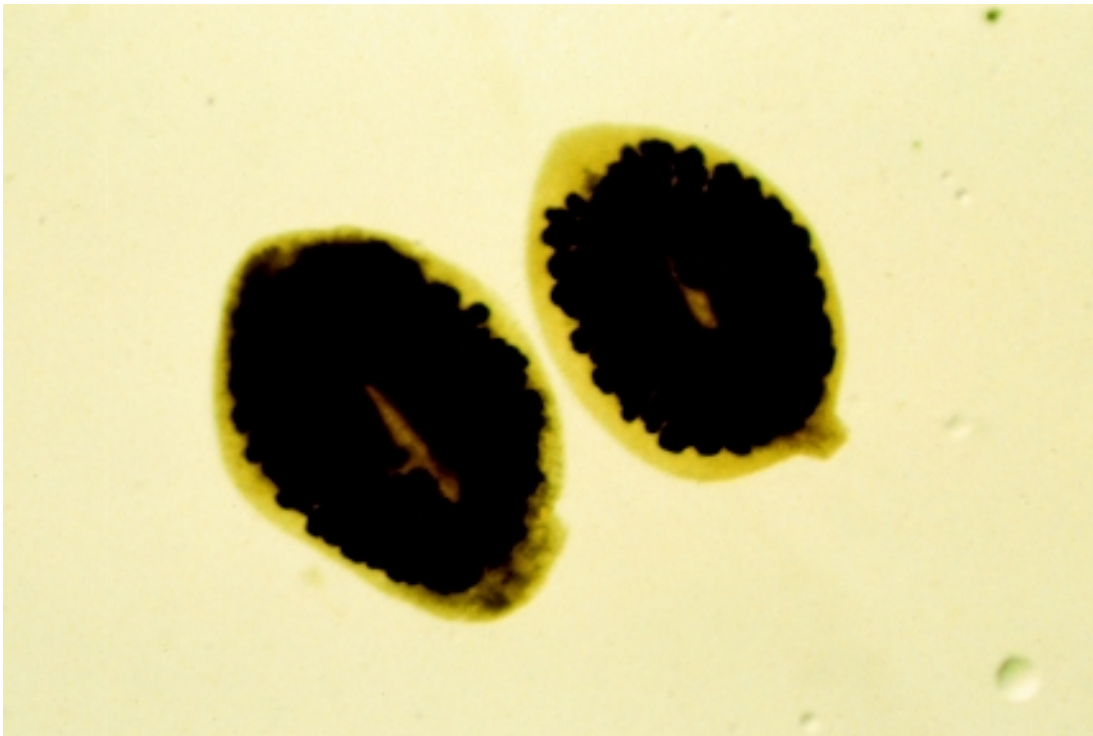


Photo by Constance L. Roderick

**Fig. 35.3** *Cyathocotyle bushiensis* from the cecae of an American coot.

*Leyogonimus polyoon* (Fig. 35.4) is a newly reported trematode in North America that caused the deaths of over 1,500 and 11,000 coots in Northeastern Wisconsin during the falls of 1996 and 1997, respectively (Fig. 35.5). This trematode is of similar small size (0.7–1.0 millimeters in length) as *S. globulus* (Fig. 35.2). It is known to cause death in coot and common moorhen in Europe, but the Wisconsin outbreaks are the first documentation of this parasite causing mortality in North America. The susceptibility of other North American birds, beside coot, remains unknown. At the Wisconsin location, various waterfowl species were dying from infections of *S. globulus* while the coot were dying from *L. polyoon* infections. None of the waterfowl were found to be infected with *L. polyoon*.

The life cycle for *L. polyoon* is not known, although the suspected first intermediate host is the snail *Bithnia tentaculata*. Investigations at the National Wildlife Health Center (NWHC) have disclosed that snails that were collected in

Wisconsin were infected with a cercariae or a larval form of the parasite that fits the literature description of *L. polyoon*. Additional studies are required to confirm that these larval forms are *L. polyoon*. Also, the intermediate host for the infective larval form or metacercariae has not yet been found. *L. polyoon* infects primarily the upper and middle areas of the small intestine. No significant field signs are associated with infection by *L. polyoon*. Gross lesions seen at necropsy include severe enteritis characterized by thickening of the intestinal wall and a fibrous-to-caseous core of necrotic debris that blocks the lumen of the intestine (Fig. 35.6).

The location where these outbreaks occurred is a lake that is drained by a stream, that is underlain with sand, and that has substantial growths of water weeds. The shoreline has been extensively developed for home sites and other human use, and the lake is used for recreation. *L. polyoon* has not been reported to infect humans.




Photo by Constance L. Roderick

**Fig. 35.4** *Leyogonimus polyoon* from the small intestine of an American coot.

**Fig. 35.5** American coot and various species of waterfowl from die-off in Shawano Lake, Wisc. Coot mortality was due to *Leyogonimus polyoon*, but waterfowl mortality was due to *Sphaeridiotrema globulus*.



Photo by K. Brockman-Mederos, Wisconsin Department of Natural Resources

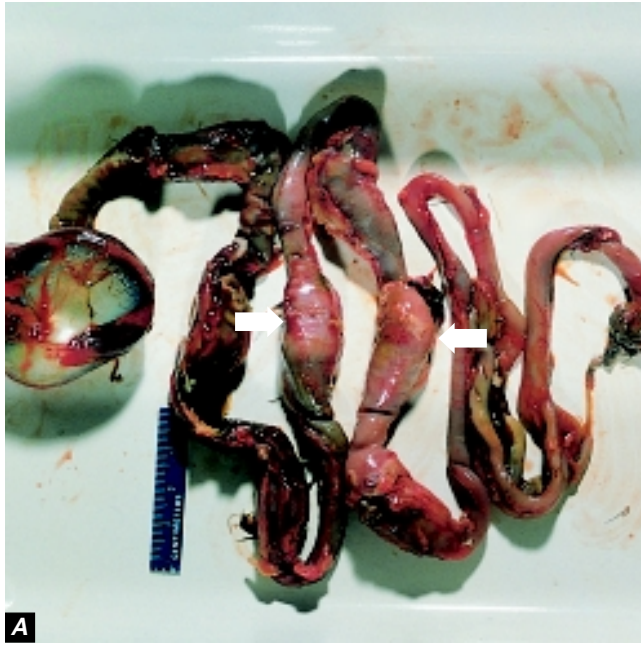


Photo by Rebecca A. Cole

**Fig. 35.6 (A)** Gastrointestinal tract from an American coot that was infected with *Leyogonimus polyoon*. Note the enlarged or swollen areas (arrows). **(B)** Intestinal tract of an American coot. The intestinal tract has been incised to expose cheesy cores of dead tissue debris caused by *Leyogonimus polyoon* (arrows).



Photo by Rebecca A. Cole

## Cestodes

Tapeworms are common in wild birds, but they seldom cause death. Heavy burdens of these parasites may reduce the vigor of the bird and serve as a predisposing factor for other disease agents, or the parasites may occlude the intestine (Fig. 35.7). One genus, *Gastrotaenia* sp., lives in the gizzard and penetrates the keratohyalin lining or the horny covering of the gizzard pads, causing inflammation and necrosis. *Cloacotaenia* sp. inhabit the ureter or the tubular area that transports wastes from the kidneys to the cloaca in some waterfowl.

## Nematodes

Trichostrongylidosis, the disease that is caused by *Trichostrongylus tenius*, is not currently a significant problem within the United States. However it is included because trichostrongylidosis, in natural populations of grouse in their native habitat in Scotland and elsewhere in the United Kingdom, demonstrates the impact that a parasite can have on the population dynamics of the bird host that it infects. *T. tenius* is a common nematode or roundworm that is found within the ceca of some types of wild birds, primarily grouse, geese, and poultry. This parasite has a direct life cycle that is closely associated with host food preferences for terrestrial vegeta-

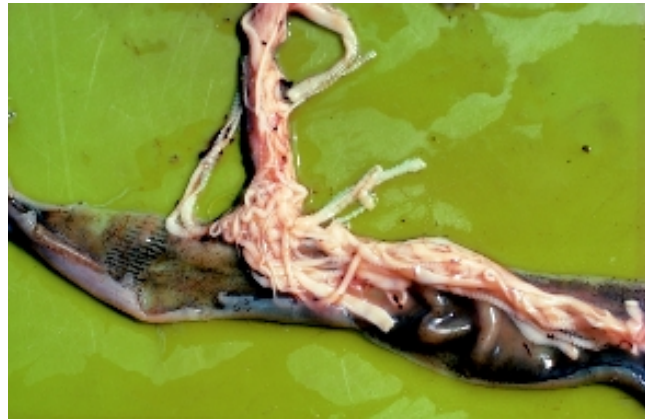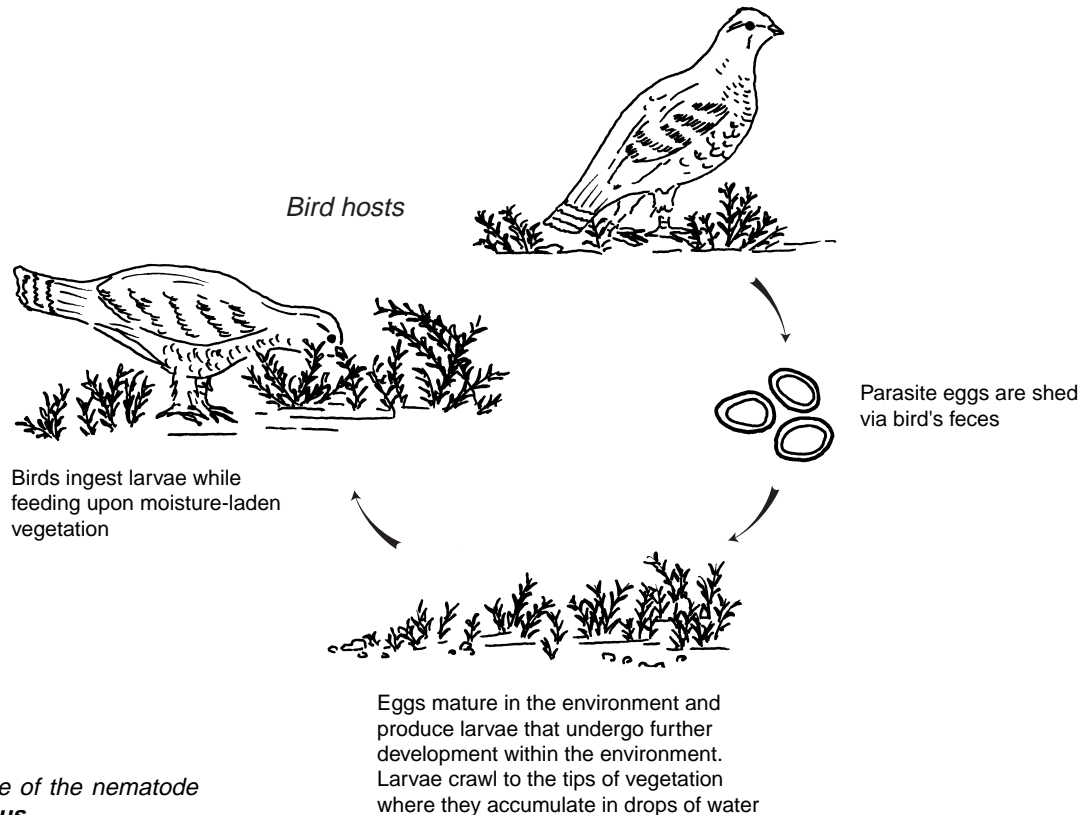


Photo by Milton Friend

**Figure 35.7** Large numbers of tape worms may occlude the intestine.

tion (Fig. 35.8). Trichostrongylidosis outbreaks can occur whenever birds are hatching because of the synchronous phase of the ecology of the parasite and the feeding habits of bird hosts.

Hatchability of the parasite eggs and survival of the free-living larval stages are moisture and temperature dependent. The parasite eggs do not develop under dry conditions and the free-living larvae are generally killed by freezing tem-



**Figure 35.8** Life cycle of the nematode *Trichostrongylus tenius*.

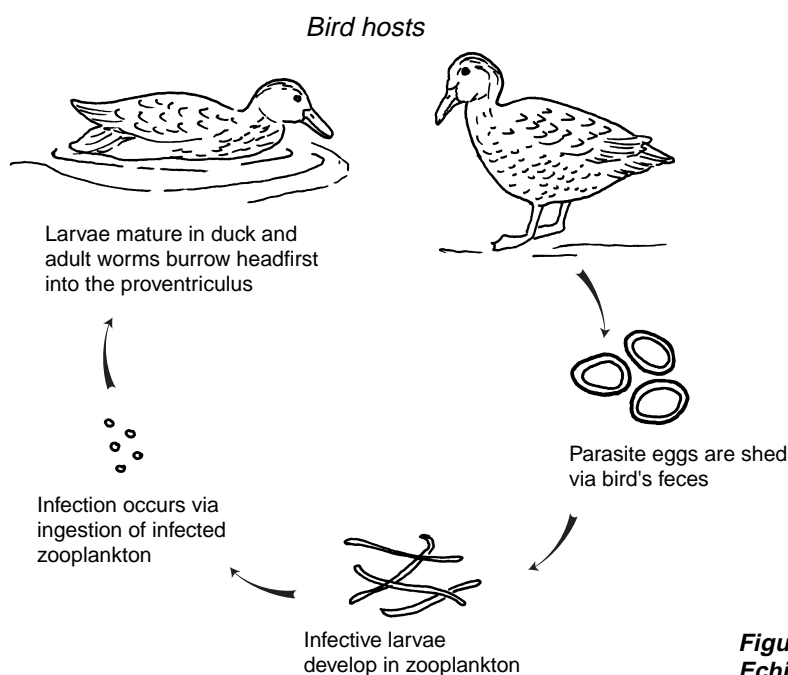
peratures. When the feces that contain the parasite eggs are kept moist and when the ambient air temperature is suitable, first-stage larvae develop within the egg and hatch in about 2 days; free-living second-stage larvae develop within another 1-1/2-to-2 days; and development to infective third-stage larvae requires an additional 8–16 days. Studies in Scotland indicate that infective larvae crawl to the tips of moist heather and accumulate there in drops of water provided by the misty weather. Grouse that feed on the tips of the heather ingest the larvae along with their food. Infective larvae molt twice more within the ceca of the bird before they become sexually mature adults.

Infections have been reported in chicken, turkey, guinea fowl, pheasant, quail, pigeons, ducks, and geese; but infections are most notable for red grouse because this parasite has clearly been shown to regulate natural populations of this species. Because adult worms can survive in their bird host for more than 2 years, all adult birds evaluated in some populations have been found to be infected, thereby, providing a reservoir for infection of young. In addition, larvae can arrest development within the ceca, overwinter, and then resume development in the spring. The temperature and moisture requirements for hatchability of the parasite eggs and survival of larvae results in synchronized availability of parasites during the period of production of young grouse. This results in the primary occurrence of disease and mortality in grouse during the spring. The hatchlings are exposed to infective larvae soon after the diet for chicks changes from insects to vegetation.

The impacts of infection by *T. tenius* are greater than just chick mortality. These parasites also decrease available energy for egg laying by adult birds. The resting metabolic rate is increased and there is a decrease in food intake by the bird. The resulting impact is reduced fecundity within the population (fewer chicks) along with high chick mortality. This combination of impacts controls population levels.

*Echinuria uncinata* is a common nematode that infects the proventriculus of various waterfowl species. The life cycle is indirect, and the parasite uses zooplankton, especially *Daphnia* sp., as intermediate hosts (Fig. 35.9). Worms mature in a duck approximately 51 days after it eats infected zooplankton. Adult worms, which are approximately 5 millimeters long, burrow headfirst into the mucosa and submucosa of the proventriculus, causing tissue swelling and inflammation. Tumor-like nodules form and can be large enough to obstruct the lumen of the proventriculus. This parasite can be especially dangerous to waterfowl where zooplankton blooms coincide with the hatching of young. Often birds that are late to hatch and do not have fully developed immune systems can consume enough infected zooplankton in a very short period of time to become severely infected. In areas where water is shallow, where zooplankton populations are numerous, and where birds are crowded into the area, this roundworm can be transmitted to many birds during a short time.

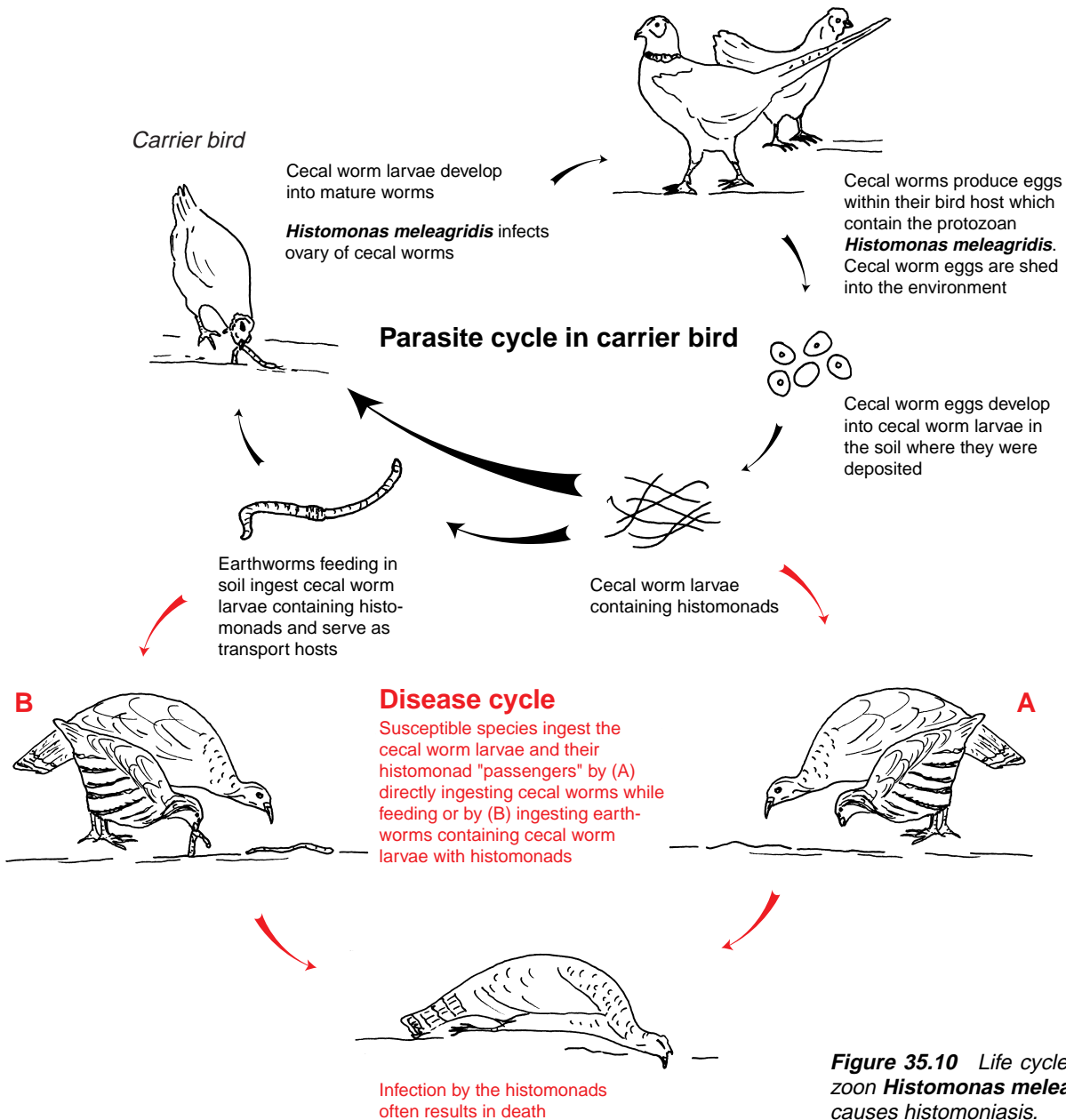
This occurred within a population of the endangered Laysan duck on Laysan Island, Hawaii during the fall of 1993. A drought had struck the island and the brine flies that the



**Figure 35.9** Life cycle of the nematode *Echinuria uncinata*.

ducks feed heavily on were believed to be scarce. This depressed food base may have resulted in a reduced level of nutrition and may have compromised the ability of the birds to withstand infections by *E. uncinata*. Birds from this die-off were severely emaciated, had thickened proventriculi, and nodules along the proventriculi and intestines. The glands within the proventriculus were severely distorted, which suggests that the function of the proventriculus was compromised. Blood samples taken from sick birds suggested that they were emaciated and severely infected with parasitic worms. It was thought that the combination of the drought, aggregation of birds around freshwater seeps, and scarce food

sources, combined with the severe parasitism, caused the ducks to die. Other examples exist where the combination of overcrowded waterfowl, a zooplankton population explosion, large numbers of infected zooplankton, and high retention of worms within waterfowl resulted in sufficient pathology by the worms to cause clinical disease and death. Maintaining fast water flow to prevent zooplankton explosions has been successfully employed for disease prevention in captive flocks such as those at waterfowl parks. *E. uncinata* is widely distributed geographically and has not been reported to infect humans.



**Figure 35.10** Life cycle of the protozoan *Histomonas meleagridis*, which causes histomoniasis.



## Protozoa

Histomoniasis is capable of causing catastrophic losses in the wild turkey, a species whose restoration has become a major wildlife management success story. *Histomonas meleagridis*, the protozoan that causes histomoniasis, utilizes the cecal worm, *Heterakis gallinarum* (a nematode), as a vector for entry into the bird hosts (Fig. 35.10). The disease is commonly called blackhead because infections sometimes cause a bluish or blackish appearance of the skin of the head in some birds due to an excessive concentration of reduced hemoglobin in the blood or cyanosis.

Earthworms and other soil invertebrates can become part of the parasite's life cycle when they feed on fecal-contaminated soil that contains cecal worm eggs infected with histomonads. The cecal worm larvae and histomonads are stored in the body of the earthworm and are transmitted to birds when worms are fed upon. However, earthworms are not required for the life cycle; cecal worm larvae that contain histomonads may be ingested by birds when they feed in a contaminated environment.

Most, if not all, gallinaceous birds are susceptible hosts. Turkey, grouse, chicken, and partridge develop severe disease and suffer high mortality rates that can exceed 75 percent of those infected. Disease is less severe in Hungarian partridge and bobwhite quail. In contrast, pheasant and some other species often do not exhibit signs of disease, but they instead become carriers that maintain the disease cycle. Canada geese that were examined at the NWHC have also been found to have a histomoniasis-like disease. In North America, wild turkey and bobwhite quail are the species most commonly infected in the wild. The disease is found worldwide.

There are no clinical signs specific to histomoniasis. Wild turkeys affected with this disease often are listless, have an unthrifty appearance of ruffled feathers, and stand with drooped wings. The birds may appear depressed, and their feces are often sulfur-yellow in color. This fecal coloration generally occurs early in the disease and, combined with other field signs, it is highly suggestive of histomoniasis. The primary gross lesions seen upon necropsy of infected birds are numerous large, pale grey, discrete circular crater-like areas of necrosis or tissue death within the liver (Fig. 35.11) and thickened caecal walls that often also become ulcerated and hemorrhagic. The lumen of the ceca may also be obstructed by aggregations of yellowish necrotic debris referred to as cecal cores (Fig. 35.12).

Disease prevention should be the major focus for addressing histomoniasis. The introduction of gallinaceous bird species that are disease carriers, such as pheasants, into habitat occupied by highly susceptible species, such as wild turkey, is unwise and it can have catastrophic results. Similarly, because chickens are often carriers of *H. gallinarum* (cecal worms), and often shed histomonads, spreading uncomposted chicken manure onto fields can distribute cecal worm eggs to wild and susceptible species.

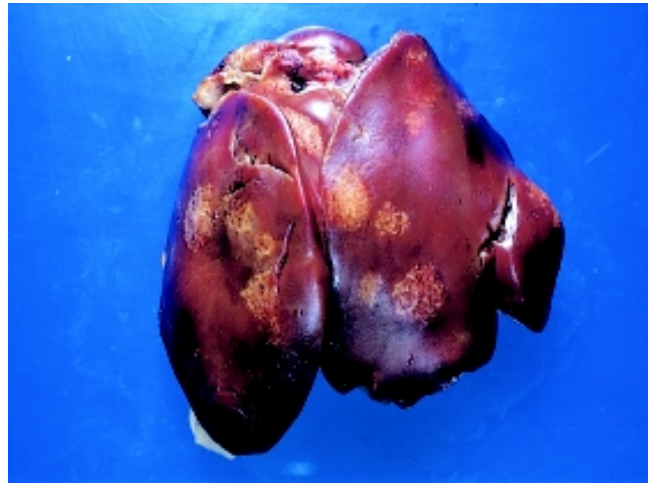


Photo by Milton Friend

**Figure 35.11** Large, pale areas in the liver of a bird infected with *Histomonas* sp.

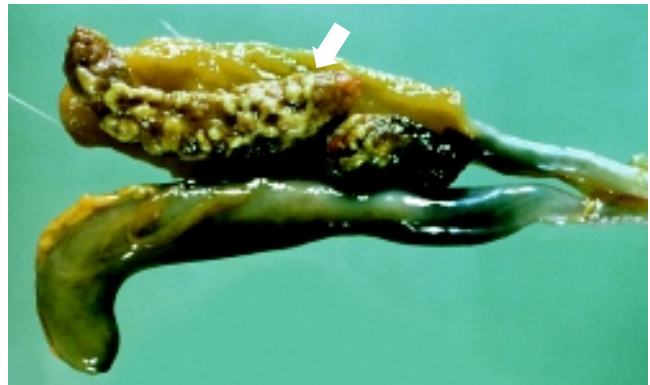


Photo by J. Christian Franson

**Figure 35.12** Cecal core (necrotic debris) in cecum of a bird infected with *Histomonas* sp.

Histomoniasis has caused the deaths of wild turkeys that were provided feed in barnyards frequented by chickens. Therefore, when attempting to reestablish wild turkey flocks in areas where they no longer exist and during periods of inclement weather that create food shortages for wild birds, placement of feed stations should be done with consideration of potential carriers of *H. meleagridis* or *H. gallinarum*.

## Ectoparasites

In addition to being vectors that transmit disease to birds, ectoparasites can be direct causes of illness and death. Just a few adult ticks feeding on a small bird can cause anemia, reduced growth, weight loss, and contribute in other ways to a depressed state of health. The fowl tick, a soft-bodied tick of the family Argasidae, is the most important poultry ectoparasite in many countries and it is often a factor limiting raising chickens and turkeys. Chickens have also been reported to suffer tick paralysis, which is a motor paralysis or paralysis of the voluntary muscles, from bites of *Argas* sp. ticks. Tick paralysis in songbirds has been associated with

the bite of the hard-bodied bird tick, *Ixodes brunneus*. Fatal paralysis from bites by this tick has been reported in numerous species of small birds. The engorged ticks in fatal cases are generally found on the bird's head and they may be attached to its eyelids. Death results from a powerful neurotoxin that is secreted by the tick while it feeds on the bird. Other species of *Ixodes* ticks have been associated with tick paralysis and mortality in marine birds, including albatross and petrels. An ascending motor paralysis that starts at the feet, progresses for 7–10 days, and ends in death has been reported.

Heavy infestations of lice, mites, fleas, flies, and other biting insects have also been responsible for causing illness and even death of wild birds, especially among nestlings. Conditions caused by these insects range from feather loss and skin damage from acariasis or mange, to myiasis or infestation with fly maggots, and anemia. Mites of the genus *Knemidocoptes* are the primary cause of mange in birds, and the mites belong to the same family (Sarcoptidae) of mites that cause mange in mammals and humans. The *Knemidocoptes* sp. mites are specific to birds and they are not a human health hazard.

More knowledge is needed about the role of ectoparasites as causes of bird death. Proper identification of the species associated with bird mortality is an important component of such assessments; therefore, the presence of insects within bird nests in which freshly dead nestlings are found should be recorded, representative parasite specimens should be collected along with any visible parasites on the carcass, and the parasites submitted should be with the carcass. Ticks and any heavy infestations of fleas, lice, and other insects on live birds being handled for banding or other purposes should also be noted, and, when practical, samples should be collected and submitted for identification to a parasitologist or disease diagnostic laboratory. An abundance of such parasites may be indicators of other health problems for the birds.

Rebecca A. Cole and Milton Friend

## Supplementary Reading

- Anderson, R.C., 1992, Nematode parasites of vertebrates, their development and transmission: Wallingford, United Kingdom, C•A•B International, University Press, 578 p.
- Arnall, L., and Keymer, I.F., 1975, Bird diseases, an introduction to the study of birds in health and disease: Bailliere Tindall, London, T.F.H. Publications, 528 p.
- Calnek, B.W. and others, 1997, Diseases of Poultry (10<sup>th</sup> ed.): Ames, Iowa, Iowa State University Press, 1,080 p.
- Delehay, T.M., Speakman, J.R., and Mass, R., 1995, The energetic consequences of parasitism: effects of a developing infection of *Trichostrongylus tenus* (Nematoda) on red grouse (*Lagopus lagopus scoticus*) energy balance, body weight and condition: Parasitology, v. 110, p. 473–482.
- Davidson, W.R., and Nettles, V.F., 1997, Field manual of wildlife diseases in the Southeastern United States (2d ed.): Athens, Ga., University of Georgia, 417 p.
- Gagnon, C., Scott, M.E., and McLaughlin, J.D., 1993, Gross lesions and hematological changes in domesticated mallard ducklings experimentally infected with *Cyathocotyle bushiensis* (Digenea): Journal of Parasitology, v. 79, p. 757–762.
- Hove, J., and Scott, M.E., 1988, Ecological studies on *Cyathocotyle bushiensis* (Digenea) and *Sphaeridiotrema globulus* (Digenea), possible pathogens of dabbling ducks in southern Quebec: Journal of Wildlife Diseases, v. 24, p. 407–421.
- Hudson, P.J., 1986, The effect of a parasitic nematode on the breeding production of red grouse: Journal of Animal Ecology, v. 55, p. 85–92.
- Huffman, J.E., and Roscoe, D., 1989, Experimental infections of waterfowl with *Sphaeridiotrema globulus* (Digenea): Journal of Wildlife Diseases, v. 25, p. 143–146.
- Mucha, K.H., and Huggman, J.E., 1991, Inflammatory cell stimulation and wound healing in *Sphaeridiotrema globulus* experimentally infected mallard ducks (*Anas platyrhynchos*): Journal of Wildlife Diseases, v. 27, p. 428–434.